


Outcomes of Hyoid Myotomy and Suspension Using a Mandibular Screw Suspension System

M. Boyd Gillespie, MD, MSc¹, Christopher M. Ayers, MPH¹,
Shaun A. Nguyen, MD, MA¹, and Michael R. Abidin, MD²

Otolaryngology—
Head and Neck Surgery
144(2) 225–229
© American Academy of
Otolaryngology—Head and Neck
Surgery Foundation 2011
Reprints and permission:
sagepub.com/journalsPermissions.nav
DOI: 10.1177/0194599810391711
http://otojournal.org


Sponsorships or competing interests that may be relevant to content are disclosed at the end of this article.

Received September 7, 2010; revised October 21, 2010; accepted November 3, 2010.

Abstract

Objective. To review the outcomes of hyoid myotomy and suspension with a mandibular screw anchoring device.

Study Design. Case series with chart review.

Setting. Academic and private sleep surgery clinics.

Methods. The study is a consecutive case series of patients undergoing hyoid myotomy and suspension using a mandibular screw suspension device as part of multilevel treatment of obstructive sleep apnea (OSA). Outcomes of interest included complication rates, change in daytime sleepiness scores, and change in apnea-hypopnea index (AHI).

Results. Ten women and 23 men with a mean age of 54 years (range, 33–73 years) underwent hyoid myotomy and suspension using a mandibular screw suspension device. Four (12%) patients experienced minor complications, including neck seroma (3 patients) and tongue edema (1 patient). Epworth Sleepiness Scale scores fell from a preoperative median of 12 to a postoperative median of 6 ($P = .002$). Ten patients (30%) refused the postoperative sleep study. In the 23 patients who underwent postoperative sleep studies, AHI scores decreased from a preoperative mean \pm SD of 40.9 ± 25.1 to 18.6 ± 21.2 postoperatively ($P = .001$). Ten patients (30%) achieved a postoperative AHI below 10. The Repose system was initially applied using a standard hyoid dissection but was later modified using a minimally invasive small incision (<2 cm) approach that demonstrated significantly fewer complications ($P = .04$).

Conclusion. Hyoid myotomy and suspension with a mandibular screw anchor is an effective method with which to address hypopharyngeal collapse in multilevel surgery for OSA. The procedure can be performed with a small-incision, minimally invasive approach with minimal complications and patient morbidity.

Keywords

obstructive sleep apnea, multilevel sleep surgery, hyoid myotomy and suspension, Repose system

Obstructive sleep apnea (OSA) is a common disorder that affects between 2% and 4% of middle-aged adults.¹ Continuous positive airway pressure (CPAP) is the first-line treatment modality for patients with moderate to severe sleep apnea. Long-term compliance with CPAP, however, is estimated to only be 50% to 70%.² Multilevel upper airway surgery is considered a salvage option in symptomatic OSA patients who fail CPAP therapy.

Uvulopalatopharyngoplasty (UPPP) has been the mainstay of upper airway surgery for OSA for the past several decades. Although highly effective for snoring, UPPP has been shown to only have a cure rate of 40% in unselected patients.³ The low rate of cure for UPPP as a stand-alone procedure is not surprising since it only addresses the velopharyngeal collapse when it has been observed that most OSA patients have multiple segments of upper airway collapse. A recent literature review of upper airway surgery for OSA demonstrated that the addition of hypopharyngeal procedures to UPPP improved the success of surgery over UPPP alone.⁴

The study presents the outcomes of a consecutive series of patients treated with hyoid myotomy and suspension (HMS) with a bone-anchored suspension suture system (Repose; Medtronic, Jacksonville, Florida). The aim of the study is to determine the success and complication rates of the procedure when performed as a component of multilevel upper airway surgery for OSA and to determine whether there are identifiable clinical factors that are associated with surgical success. In addition, the study describes a later modification in the

¹Department of Otolaryngology—Head & Neck Surgery, Medical University of South Carolina, Charleston, South Carolina, USA

²Metropolitan ENT, Alexandria, Virginia, USA

This article was presented at the 2010 AAO-HNSF Annual Meeting & OTO EXPO; September 26–29, 2010; Boston, Massachusetts.

Corresponding Author:

M. Boyd Gillespie, MD, MSc, Department of Otolaryngology—Head & Neck Surgery, 135 Rutledge Avenue MSC 550, Charleston, SC 29425-5500, USA
Email: gillesmb@musc.edu

HMS technique that can be performed in a minimally invasive fashion with a lower rate of complications.

Materials and Methods

Study Design

The study is a retrospective case series of 33 adult patients (age >18 years) who underwent HMS using a mandibular screw anchoring device (Repose; Medtronic) over a 4-year period. All patients were evaluated at the Medical University of South Carolina (MUSC) Snoring Clinics in Charleston, South Carolina, or Metropolitan ENT in Alexandria, Virginia. Patients were identified by searching billing data for the HMS CPT code 21685. Data included in this study were obtained from the electronic medical records of the Medical University of South Carolina and from the office charts of Metropolitan ENT. Data acquired from the chart included patient demographics, pre-Epworth Sleepiness Scale (ESS) and post-ESS scores, pre-apnea-hypopnea index (AHI) and post-AHI and lowest oxygen saturation levels, extent of multilevel surgery, hyoid myotomy technique, and complication rate. The MUSC institutional review board granted approval for this study.

Patient Evaluation

All patients presented with a history of OSA documented by overnight polysomnography. The patients were seeking surgical evaluation to determine the feasibility of surgical salvage of CPAP failure. Each patient received a comprehensive sleep history and physical examination, including supine upper airway endoscopy. The patients in this series were found to have compromised hypopharyngeal airspaces on awake supine endoscopy with contact between the epiglottis and the posterior pharyngeal wall and were therefore considered candidates for HMS.

Surgical Procedure

All 33 patients underwent multilevel sleep surgery for CPAP salvage, which included HMS using the Repose mandibular screw anchoring device. Initially, the procedure was performed using standard technique through a 4- to 5-cm incision in a neck crease overlying the hyoid bone followed by complete skeletonization of the central segment of the hyoid by releasing the infra- and suprahyoid musculature between the lesser cornu ($n = 16$ patients). The technique was later modified to a minimally invasive technique using a limited 2-cm incision with minimal muscular release ($n = 17$ patients; **Figure 1**). The later technique, described below in detail, became the preferred technique since it was faster to perform, did not require placement of a drain, and had fewer overall complications.

Minimally Invasive HMS Technique

A 2-cm incision is made in the mentum just posterior to the chin after injection of lidocaine 1% (or alternatively Marcaine 0.05%) with 1:100 000 epinephrine. A right angle clamp is used to dissect the underlying tissue to the posterior table of the mandible. A separate 2-cm incision is then made over the hyoid bone. The soft tissue overlying the hyoid is then

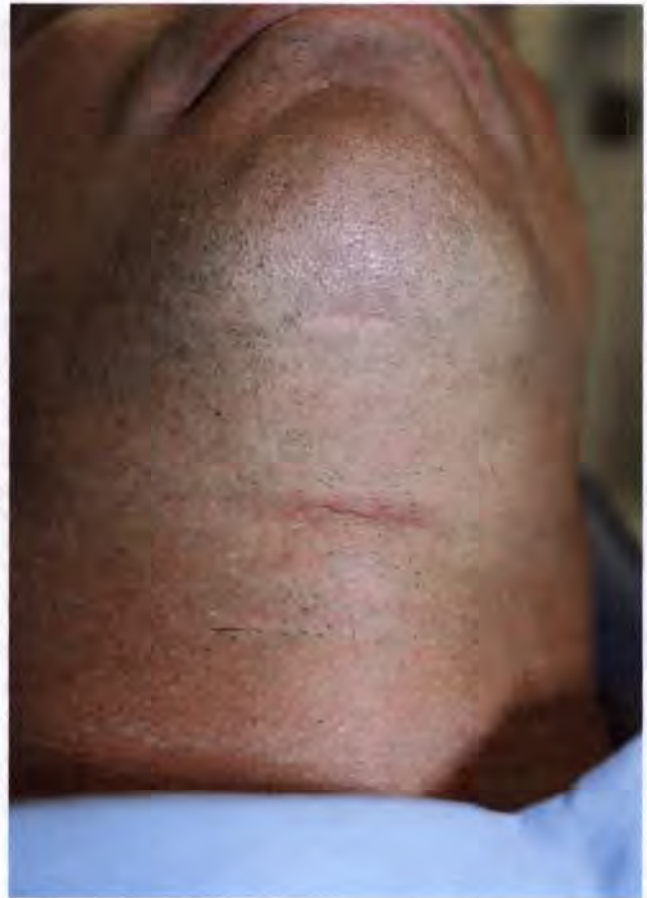

Figure 1. Postoperative appearance of neck incisions in a patient who received the minimally invasive hyoid myotomy and suspension technique.

released with needlepoint cautery. The central hyoid bone is then grasped off the midline on the side of the surgeon with an Allis clamp. The bovie is then used to skeletonize the central 1 to 2 cm of hyoid bone at the infrahyoid musculature, followed by placement of a second stabilizing Allis off the midline away from the surgeon.

With the Repose screw inserter, 2 swaged screws are inserted into the submental incision with placement of the screws into the posterior table of the mandible just off the midline on either side. The sutures are then passed with a wire puller under the skin and out the hyoid incision. Each double-armed suture is attached to a half-curved free noncutting needle, and 2 heavy needle holders are used to pass the sutures from inferior around the hyoid bone. The attached Allis clamp stabilizes the hyoid, and the needle is passed under the hyoid just off the midline. While maintaining hold of the needle, the second needle holder is used to grasp the needle blindly parallel to its long axis. Often one has to release the initial needle holder and use the other needle holder to “walk” the needle around the hyoid. Once both of the sutures are passed around the hyoid, a double throw is applied to each suture. The hyoid is then retracted anteriorly and superiorly with significant force in the anatomic position, and the sutures are cinched up

Table 1. Description of Patients Undergoing Multilevel Upper Airway Surgery With Hyoid Myotomy and Suspension

Patient Variable	
Female, No. (%)	10 (30)
Male, No. (%)	23 (70)
Mean age, y (range)	54 (33-73)
Mean BMI (range)	32 (23-45)
Median ESS score (range)	12 (4-22)
Mild apnea (AHI <15), No. (%)	3 (9)
Moderate apnea (AHI 16-30), No. (%)	14 (42)
Severe apnea (AHI >30), No. (%)	16 (49)
Associated procedures, No. (%)	
HMS alone	2 (6)
UPPP	20 (61)
Septoplasty/turbinate reduction	7 (21)
Radiofrequency palate	3 (9)
Radiofrequency tongue base	2 (6)

Abbreviations: AHI, apnea-hypopnea index; BMI, body mass index; ESS, Epworth Sleepiness Scale; HMS, hyoid myotomy and suspension; UPPP, uvulopalatopharyngoplasty.

and tied together in the midline. The wounds are then irrigated and closed in the standard fashion with the placement of foam tape as a pressure dressing. No drain is used.

Follow-Up

Patients received routine follow-up in the postoperative period to monitor surgical healing and manage any complications. All patients were encouraged to undergo a repeat polysomnography 12 weeks after surgery to document the presence of improvement in sleep-related respiratory parameters.

Statistical Methods

All analyses were performed with Sigma Stat 3.5, SPSS 15.0, and Sample Power 2.0 software (SPSS, Inc, an IBM Company, Chicago, Illinois). All continuous variables were normal distributed as determined by the Kolmogorov-Smirnov test. Pre treatment and posttreatment outcome measures were analyzed using tests for paired data, including the Wilcoxon signed rank test for ordinal scales (Epworth) and paired *t* test for continuous variables (AHI; lowest O₂ saturation). A multiple linear regression model was used with the following predictor variables: gender, age, body mass index (BMI), preoperative AHI, UPPP, and HMS technique. A *P* value of less than .05 was considered indicative of statistical significance.

Results

The study identified 10 female and 23 male patients of a mean age of 54 years (range, 33-73 years) who underwent the HMS procedure with the mandibular screw suture suspension device (Repose; Medtronic) over a 4-year period. The patients were largely obese with moderate to severe levels of OSA (Table 1). UPPP was the procedure most frequently performed in conjunction with the HMS. Standard HMS dissection using a long incision (4-5 cm) with extensive release of

Table 2. Overall Outcomes Before and After Multilevel Upper Airway Surgery With Hyoid Myotomy and Suspension in Patients With Evaluable Postoperative Polysomnography

Outcome Variable (n = 23)	Pre	Post	P Value
AHI, mean (SD)	40.9 (25.1)	18.6 (21.2)	.001
Lowest O ₂ saturation, mean (SD)	79.1 (11.7)	80.7 (9.6)	.58
Epworth Sleepiness Scale, mean (SD)	12.1 (5.2)	6.2 (3.8)	.002
Surgical success (>50% reduction in AHI and final AHI <20), No. (%)		16/23 (70)	
Final AHI <10, No. (%)		10/23 (43)	

Abbreviation: AHI, apnea-hypopnea index. *P* values calculated by paired *t* test (AHI; lowest O₂ saturation) and Wilcoxon signed rank test (Epworth).

the supra- and infrahyoid musculature was performed on 16 patients until the development of a minimally invasive, 2-cm incision approach with minimal dissection of the infrahyoid attachments, which was performed on 17 patients.

All patients were evaluated in the immediate postoperative period. Four patients (17%) undergoing standard HMS dissection experienced procedure-related complications. Three of these patients developed neck seromas in the week following surgery despite the use of Penrose drains during the first 24 hours postoperatively. The seromas responded to serial aspiration and pressure dressings. One patient developed significant tongue edema in the immediate postoperative period requiring a 48-hour inpatient stay for intravenous fluids and steroids. There were no cases of prolonged (>48 hours) dysphagia prohibiting oral intake. There were no observed complications in patients who received the minimally invasive technique despite immediate closure of the wound without a drain. The difference in complication rates between the standard HMS dissection (4/16) and the minimally invasive approach (0/17) was statistically significant (*P* = .04).

The outcomes of multilevel upper airway surgery with HMS are listed in Table 2. Although postoperative sleep studies were recommended for all patients at 12 weeks postsurgery to evaluate surgical response, 10 patients refused to undergo follow-up sleep studies, leaving 23 patients evaluable by polysomnographic criteria. There was significant reduction in both ESS and AHI postoperatively; however, the lowest oxygen saturation reached during sleep was unchanged. The individual pre- and postoperative AHI outcomes are presented in Figure 2. One patient (13%) who underwent a postoperative polysomnogram demonstrated worsening of AHI from 57 to 67. This female patient was older (60 years) and more obese (BMI 45.5 kg/m²) than the mean for the cohort. Of the 2 patients who underwent hyoid myotomy alone without associated procedures,



Figure 2. Individual preoperative and postoperative apnea-hypopnea index (AHI) outcomes.

1 underwent the postoperative sleep study with overall AHI falling from 62 to 14. This patient was a 45-year-old man with a BMI of 31.6 kg/m². The majority of patients were surgical successes by classically defined criteria, and 10 patients achieved minimal levels of persistent apnea.

A univariate analysis suggested a significantly higher surgical success with the minimally invasive HMS technique (14/17 patients) compared to the standard HMS technique (2/6 patients) ($P = .045$), but this comparison was no longer significant after controlling for other patient variables (gender, age, BMI, preoperative AHI, use of UPPP, HMS technique; $P = .32$).

Discussion

Multilevel upper airway surgery for CPAP salvage has evolved over the past 20 years in an effort to improve the relatively limited surgical success rates observed with UPPP alone. Multilevel upper airway surgery includes a variety of procedures to both enlarge the lumen and reduce the collapsibility of the upper airway during sleep. Currently, there is no readily defined standard by which to decide which combinations of procedures work best for a given patient. Factors that go into surgical decision making include physiologic variables (eg, BMI), anatomic factors (eg, craniofacial structure, tongue and tonsil size), sleep apnea severity, findings on upper airway fiber-optic endoscopy, and patient preference.

Procedures proposed for the treatment of hypopharyngeal collapse include mandibular osteotomy, genioglossus advancement, and HMS. The use of HMS for OSA was initially described by Riley et al,⁵ who described suspending the hyoid with fascia lata passed around the hyoid and sutured to the mandibular periosteum. The same group of authors later proposed a revised HMS technique where the hyoid was brought anteriorly and secured to the superior border of the thyroid cartilage with permanent suture through a single cervical incision.⁶

The Repose (Medtronic) suspension suture system was first introduced in the late 1990s as a device to provide stabilization to the tongue during sleep. The Repose tongue stabilization procedure involved using a special drilling device to place a screw with an attached permanent suture on the lingual surface of the mandible at the level of the genioglossus

tubercle. The suture was then looped around the base of the tongue with specialized trochars and tied under tension to keep the tongue base forward during supine sleep. Surgeons familiar with the Repose system readily adapted it to HMS by looping the hyoid bone with the permanent sutures attached to screws on the lingual surface of the mandible and tying the sutures in a fashion that lifts the hyoid in an anterior-superior direction. The present study is the first to describe the outcomes of the Repose HMS technique in a moderate-size group of patients undergoing multilevel upper airway surgery for CPAP salvage. The study also describes how Repose HMS can be performed with a minimally invasive technique that reduces wound-related complications.

The effectiveness of HMS in improving the outcomes of sleep surgery is subject to debate. An evidence-based literature review found that the thyrohyoidopexy HMS technique has a mean success rate of 50% (range, 17%-78%) in the combined 101 patients from 4 studies when performed in conjunction with a previous or simultaneously performed palate surgery, which is only marginally better than the 40% success rate of UPPP.⁴ A separate study found that only 21% (6/29) of patients undergoing the revised thyrohyoidopexy HMS technique with a previous or simultaneously performed UPPP achieved a 50% reduction in AHI and an overall AHI <20. The authors of this study, however, noted that their patient population was significantly more obese (mean BMI 34.1) than other series that reported better success in less obese patients.⁷

The present study observed a success rate of 70% in patients undergoing a postoperative sleep study after multilevel upper airway surgery with the Repose HMS technique. There are several potential reasons for the relatively high level of success observed in these patients. First, the patients selected for HMS demonstrated evidence of epiglottic prolapse against the posterior pharyngeal wall during awake, supine endoscopy. The authors propose that HMS may be more effective at pulling the epiglottis anteriorly via the hyoepiglottic ligament than at stabilizing or advancing the base of tongue. Second, the anterior-superior vector is the normal vector of the hyoid during swallow and allows for greater displacement than the more anterior-inferior vector of a thyrohyoidopexy. Last, the technique avoids extensive skeletonization of the muscular attachments of the hyoid, which may potentially worsen tongue stability when divided. It is important to note that the improvement in AHI in this study did not result in significant improvement in the lowest measured oxygen saturation level. This is likely because it has been observed that even patients with surgical success often have residual levels of apnea, some of which may be associated with significant declines in oxygen saturation. Other measures of oxygen level, such as the mean low oxygen level or oxygen desaturation index, would be more reflective of the improved AHI. Therefore, these parameters should be included in future studies.

The study is limited by its retrospective, nonrandomized design and limited sample size. Similar to many studies of multilevel sleep surgery, the study demonstrates mixed effects that make it difficult to discern the exact contribution of HMS to improvements in sleep-related parameters. Future studies may

benefit from the inclusion of a control group undergoing multi-level sleep surgery without HMS. In addition, a high percentage of patients elected to not undergo postoperative sleep studies against medical advice. This is possibly because of subjective sleep improvement or out of fear that the surgery has failed and that CPAP would be recommended again. Although a univariate analysis suggested that surgical success was associated with the minimally invasive hyoid technique, this association was no longer present when controlling for other patient factors. The small number of patients with postoperative sleep studies reduced the probability of identifying factors associated with surgical success with multiple regression analysis due to insufficient power.

Conclusions

HMS with a mandibular screw anchor is a reasonable surgical option with which to address hypopharyngeal collapse in multi-level surgery for OSA. The procedure can be performed with a small-incision, minimally invasive approach with minimal complications and patient morbidity. Short-term improvement in polysomnographic parameters is encouraging but will require further study because of limited sample size. Future randomized studies would clarify the association of HMS to changes in sleep-related parameters and help better define which patients are more likely to respond to the procedure.

Author Contributions

M. Boyd Gillespie, design, data collection, data analysis, manuscript preparation; **Christopher M. Ayers**, design, data collection, data analysis, manuscript preparation; **Shaun A. Nguyen**, data analysis, manuscript preparation; **Michael R. Abidin**, design, data collection, data analysis, manuscript preparation.

Disclosures

Competing interests: M. Boyd Gillespie has a consulting agreement with Medtronic for the development of a new sleep surgery device. There has been no consulting with regard to the Repose device.

Sponsorships: None.

Funding Source: None.

References

1. Young T, Palta M, Dempsey J, Skatrud J, Weber S, Badr S. The occurrence of sleep-disordered breathing among middle-aged adults. *N Engl J Med*. 1993;328:1230-1235.
2. Richard W, Venker J, den Herder C, et al. Acceptance and long-term compliance of nCPAP in obstructive sleep apnea. *Eur Arch Otorhinolaryngol*. 2007;264:1081-1086.
3. Sher AE, Schechtman KB, Piccirillo JF. The efficacy of surgical modifications of the upper airway in adults with obstructive sleep apnea syndrome. *Sleep*. 1996;19:156-177.
4. Kezirian EJ, Goldberg AN. Hypopharyngeal surgery in obstructive sleep apnea: an evidence-based medicine review. *Arch Otolaryngol Head Neck Surg*. 2006;132:206-213.
5. Riley RW, Powell NB, Guilleminault C. Obstructive sleep apnea syndrome: a review of 306 consecutively treated surgical patients. *Otolaryngol Head Neck Surg*. 1992;108:117-125.
6. Riley RW, Powell NB, Guilleminault C. Obstructive sleep apnea and the hyoid: a revised surgical procedure. *Otolaryngol Head Neck Surg*. 1994;111:717-721.
7. Bowden MT, Kezirian EJ, Utley D, Goode RL. Outcomes of hyoid suspension for the treatment of obstructive sleep apnea. *Arch Otolaryngol Head Neck Surg*. 2005;131:440-445.